



Manifestations of gastrointestinal diseases in the oral cavity

Nabil El-Lababidi

Types of mouth affections in conjunction with GIT diseases I.

- Glossitis:

- Crohn's disease
- Coeliac disease
- Kwashiorkor
- Malabsorption syndromes
- Gastro-duodenal ulcers

- Teeth disorders:

- Coeliac disease
- Gardner syndrome

- Ulcers, erosions:

- Crohn's disease
- Ulcerative colitis
- Coeliac disease
- Malabsorption syndromes

- Candidiasis:

- Steroid treatment

- Lip affections:

- Crohn's disease

Types of mouth affections in conjunction with GIT diseases II.

- Gingivitis:
 - Crohn's disease
 - Coeliac disease
- Tingling sensations of the mouth:
 - Coeliac disease
 - Malabsorption syndromes
- Cheilitis:
 - Crohn's disease
 - Coeliac disease
 - Malabsorption syndromes
- Pigmentations:
 - Peutz-Jeghers syndrome

Coeliac disease I.

- Malabsorption syndrome
- Permanent gluten (gliadin) intolerance
- Gliadin is mainly in oats, rye, wheat and barley
- Etiology is unclear. A coincidence of genetic predisposition and autoimmune mechanisms is suspected
- Heavily underdiagnosed. Estimates are that 1% of North American population is affected. 90% of patients are still undiagnosed!
- Increased risk of developing coeliac disease in patients with:
 - Diabetes Mellitus type 1
 - Autoimmune thyroiditis
 - Down's syndrome

Coeliac disease II.

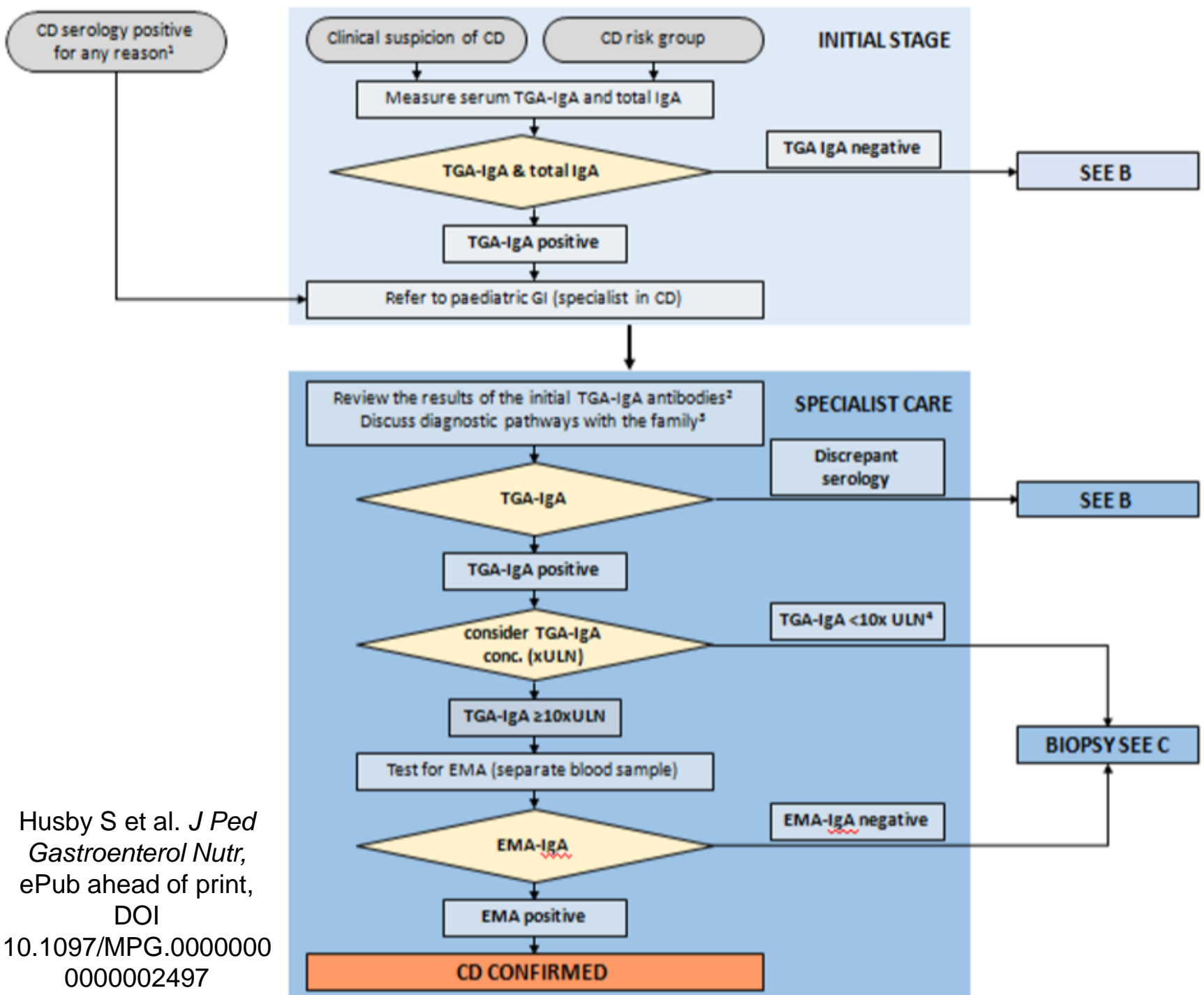
- Clinical manifestations:
 - Typical:
 - Abdominal pain
 - Diarrhea
 - Weight loss, failure to thrive, growth delay
 - Other:
 - Anemia
 - Significant weakness
 - Osteoporosis
 - Menstrual cycle disorders/infertility
 - Delayed puberty
 - Dermatitis herpetiformis Dühring

Coeliac disease III.

- Clinical manifestation in the oral cavity:
 - *Enamel defects*
 - Delayed teeth eruptions
 - *Recurring mouth ulcers*
 - Cheilosis
 - Oral lichen ruber planus
 - Atrophic glossitis

Coeliac disease IV.

- Laboratory diagnosis:
 - Whole IgA levels (selective IgA deficiency incidence = 1:600!)
 - Anti tissue transglutaminase antibodies
 - Anti endomysial antibodies



Husby S et al. *J Ped Gastroenterol Nutr*,
 ePub ahead of print,
 DOI
 10.1097/MPG.00000000
 0000002497

Coeliac Disease VI.

- Treatment:
 - Life long, strict, gluten-free diet

Gastro-oesophageal reflux I.

- Dental enamel destruction caused by gastric acids in patients with chronic gastro esophageal reflux in:
 - Gastro esophageal reflux disease
 - Hiatal hernia
 - Bulimia nervosa
- Loss of dental enamel in the surfaces exposed to gastric acids, so called erosions
- The maximum teeth damage in bulimic patients is in the oral surfaces of the upper frontal teeth
- Eroded dental enamel is smooth, shiny and hard
- In cases of long term damage the tooth dentin can be seen as a brown-greenish streaming. Teeth are sensitive to thermal stimuli

Jaundice I.

- Excessive bilirubin accumulates in tissues including the oral mucosa thus leading to their yellowish discoloration
- The degree of the yellowish discoloration depends on the bilirubin levels and on the duration of hyperbilirubinemia
- Bilirubin has affinity to elastin » increased accumulation in the tongue frenulum and the soft palate
- Cave! Similar discolorations can be seen in patients with excessive vitamin A intake!
- In childhood, biliverdin forms teeth depositions » yellowish to greenish discoloration of the teeth, for instance in children with biliary atresia

Peutz-Jeghers syndrome I.

- Mutation in the LKB1 gene
- Autosomal dominant pattern of inheritance or sporadic mutations
- Associated with hamartomas affecting mainly the thin intestine and perioral and oral pigmentations
- Flat, painless, brown spots in the oral cavity, mainly on the buccal mucosa, tongue and lips
- Microscopically, acanthosis with increased melanocytes and near-by keratinocytes pigmentation is present
- Treatment is not necessary, only for social or cosmetic reasons
- Zaheri et al. have proven good results of ablation with potassium-titanyl-phosphate laser

Gardner syndrome I.

- Autosomal dominant pattern of inheritance, rarely, spontaneous mutation in a gene on the 5th chromosome
- Clinical manifestations include:
 - Intestinal polyposis with high risk of malignant transformation
 - Skin manifestations:
 - Epidermoid cysts
 - Fibromas
 - Sebaceous cysts
 - Bone manifestations:
 - Osteomas of the skull
 - Tumors of the thyroid gland

Gardner syndrome II.

- Affections of the head and neck usually appear during childhood or adolescence:
 - Multiple enostoses of the jaws, usually affection the teeth alveoli, asymptomatic
 - Supernumerary and/or missing teeth:
 - Usually affecting the canine teeth and sparing molars
 - Supernumerary teeth usually wedge-shaped
 - Increased risk of odontomas, in the same distribution like in supernumerary teeth
 - Osteomas of the jaws and paranasal cavitis
 - Epidermoid cysts of the head and the neck

Gardner syndrome III.

- A dentist can alert the gastroenterologist in regards to the possibility of Gardner syndrome via oral manifestations
- According to Ide et al. :
 - Patients with 3 – 6 jaw osteomas are suspicious of Gardner syndrome
 - Patients with more than 6 osteomas are regarded as diagnosed with Gardner syndrome until proven different

Inflammatory Bowel Disease

Crohn's Disease

- Transmural inflammation of the GIT wall
- Can affect any part of the GIT, traditionally the ileocecal region
- Histological findings of granulomas

Ulcerative colitis

- Inflammation affecting only the GIT mucosa
- Affecting only the thick intestines, always starting at the rectum and spreading orally
- Histological findings of crypts and crypt abscesses

It is impossible to differentiate these two units solely based on oral findings

Oral manifestations of Crohn's disease I.

- According to Dupuy et al. only in 0.5% of patients with Crohn's disease
- Patients with oral manifestations are more likely to have affections of the esophagus and the anus
- Male predominance, usually manifests in early age
- Rarely, oral manifestations can be the first presentation of Crohn's disease
- Usually multifocal, linear, nodular, polypoid or diffuse affections of the oral mucosa
- Predilection of affecting the labial and buccal mucosa
- Usually hard, pink and painless
- Painful on touch or due to ingestion of acidic, spicy or hot food only when ulcers are present
- Ulcers can be persistent, linear and deep » diff. dg. blisters

Oral manifestations of Crohn's disease II.

- Microscopically:
 - Subepithelial, non-caseating granulomas. Characteristic epithelioid histiocytosis, large-cell and lymphocytic infiltrate
 - The changes are identical to those seen in the intestines
- Oral manifestations are typically persistent, remitting and relapsing
- Response to systemic treatment is individual, variable and unpredictable
- Oral manifestations don't always correspond with the degree of GIT inflammation activity
- Some oral ulcers respond to topical or infiltrative administration of steroids

Oral manifestations of ulcerative colitis I.

- Affections of the oral cavity are called pyostomatitis vegetans
- Very rare, much rarer than oral manifestations in Crohn's disease
- Male predominance
- Oral manifestations can develop at any age
- They can precede GIT manifestations but usually they appear at a similar time
- They are pustules on a red basis, affecting any part of the oral cavity with the exception of the dorsum of the tongue
- Long lasting lesions can granulate or appear as polypoid shape or rippled
- Some patients have ulcers of the oral cavity
- 10% of patients with oral manifestations also have arthritis of the temporomandibular joint

Oral manifestations of ulcerative colitis II.

- Microscopically:
 - Crypt abscesses with lack of granulomas
 - Similar to changes of the thick intestine
 - Inflammatory infiltration with neutrophile, eosinophile and lymphocyte predominance is usually present
- Oral manifestations usually respond well to systemic steroid treatment
- Oral manifestations usually correspond with the degree of thick intestine inflammatory activity

Thank you for your attention!

